ALPHA GROUP
MEDICINA INTEGRATIVA

Maria Emilia Gadelha Serra
Médica
CREMESP 63451
emilia.gadelha1@gmail.com

LAUDO MÉDICO-PERICIAL

Maria Emilia Gadelha Serra, médica inscrita no Conselho Regional de Medicina do Estado de São Paulo (CREMESP) sob o no. 63.451 e no Conselho Regional de Medicina do Distrito Federal (CRM DF) sob o no. 28.803, graduada pela Universidade Federal do Rio de Janeiro (UFRJ) em 1988 e Pós-graduada em Perícias Médicas pelo Curso de Especialização em Perícias Médicas/Medicina Legal da Faculdade de Ciências Médicas da Santa Casa de São Paulo, atesto para os devidos fins, que **analisei o prontuário médico integral de Bruno Oscar Graf a pedido e com autorização de sua família (dos pais Arlene Teresinha Ferrari Graf e Oscar José Graf) em 22 de setembro de 2021.**

O paciente, masculino, **nascido em 28 de outubro de 1992**, 28a9m, **falecido em 26 de agosto de 2021** em decorrência de **Acidente Vascular Encefálico Hemorrágico** (associado a volumoso hematoma cerebral parietal, além de vários pontos de hemorragia em lobo frontal, diagnosticado em 24 de agosto de 2021) secundário à **Trombocitopenia Trombótica Imune Induzida por Vacina SARS-Cov-2 ("Vaccine-induced Immune Thrombocytopenia and Thrombosis" - VITT)**, tipo **AstraZeneca, Lote 218185, recebida no dia 14 de agosto de 2021**, em Blumenau, Estado de Santa Catarina **(ANEXO 1). Os sintomas clínicos se iniciaram em 21 de agosto de 2021, portanto 7 (sete) dias após o recebimento da referida vacina.**

De acordo com a Sociedade Americana de Hematologia, a VITT é atualmente definida como uma **síndrome clínica caracterizada por todas as anormalidades laboratoriais e radiológicas anormais descritas abaixo que ocorrem em indivíduos 4 (quatro) a 30 (trinta) dias** após a vacinação com a vacina Ad26.COV2 ou ChAdOx1 nCoV-19 (vacina de vetor viral que é produzida no Brasil pela Fiocruz em parceria com a indústria farmacêutica AstraZeneca).

- O desenvolvimento de trombose em locais incomuns inclui trombose do seio venoso cerebral / trombose venosa esplâncnica
- Trombocitopenia (baixa de plaquetas – células da coagulação) leve a grave. No entanto, uma contagem normal de plaquetas não exclui a possibilidade dessa síndrome em seus estágios iniciais
- Anticorpos positivos contra o fator plaquetário 4 (PF4) identificados pelo ensaio de imunoabsorção enzimática (ELISA).

ALPHA GROUP
MEDICINA INTEGRATIVA

Maria Emilia Gadelha Serra
Médica
CREMESP 63451
emilia.gadelha1@gmail.com

Vários outros estudos se referem à VITT. Um estudo em especial, publicado na revista New England Journal of Medicine em junho de 2021, identificou um sinal de alerta de particular preocupação em relação a novos eventos adversos da vacina ChAdOx1 nCoV-19 (AstraZeneca). Trata-se da ocorrência de uma nova síndrome – "Vaccine-induced Immune Thrombocytopenia and Thrombosis" (VITT) – uma constelação clínica incomum de coagulação anormal (com aumento de dímeros D e redução de fibrinogênio), associada particularmente à trombose venosa cerebral e baixa de plaquetas (trombocitopenia) que **ocorre entre 5 (cinco) a 48 (quarenta e oito) dias (média de 14 – quatorze - dias) após a 1ª. dose da vacina, que resultou em morte em 22% dos casos no estudo referido. O teste de anticorpos para o Fator Plaquetário 4 (PF4) foi positivo, à semelhança do que acontece na trombocitopenia induzida pela heparina (anticoagulante).** Os altos títulos de anticorpos anti-PF4 ativam as plaquetas, consumindo-as e levando à formação de trombos em diversas localizações. Os eventos de trombose foram principalmente trombose venosa cerebral, mas também incluíram trombose arterial, trombose da veia esplâncnica e da veia porta (no abdômen) e também tipos mais comuns de tromboembolismo venoso, como trombose venosa de membros inferiores e embolia pulmonar. A baixa crítica do número de plaquetas pode se associar a sangramentos incontroláveis, principalmente se ocorrem dentro do cérebro. Outro estudo relatou a taxa de óbito em 60%, dada a gravidade do quadro e dificuldade de manejo clínico.

O exame de anticorpo anti-heparina PF4 (Fator Plaquetário 4) utilizando a técnica de Enzimaimunoensaio de Bruno Oscar Graf foi coletado em 24 de agosto de 2021 e retornou POSITIVO (ANEXO 2), confirmando o diagnóstico de Trombocitopenia Trombótica Imune Induzida por Vacina SARS-Cov-2 (VITT) associado à vacina AstraZeneca, que motivou o óbito de Bruno Oscar Graf por hemorragia cerebral maciça 12 (doze) dias após o recebimento da vacina AstraZeneca. No **ANEXO 4** constam 11 (onze) referências científicas que embasam o presente laudo.

Sendo o que havia a relatar, discutir e expor, permaneço à disposição para esclarecimentos adicionais e encerro o presente laudo médico-pericial contendo 20 (vinte) folhas, sendo a última folha assinada.

São Paulo, 22 de setembro de 2021.

Maria Emilia Gadelha Serra
Médica

Maria Emilia Gadelha Serra
Médica
CREMESP 63451
emilia.gadelha1@gmail.com

ANEXO 1

Carteira de Vacinação de Bruno Oscar Graf

PREFEITURA DE BLUMENAU
SECRETARIA DE PROMOÇÃO DA SAÚDE
CARTÃO DE VACINAÇÃO ADULTO

NOME	Bruno Oscar Graf
NOME DA MÃE	
CNS	DATA DE NASCIMENTO 28-10-92
ENDEREÇO	
CIDADE / UF / TELEFONE	

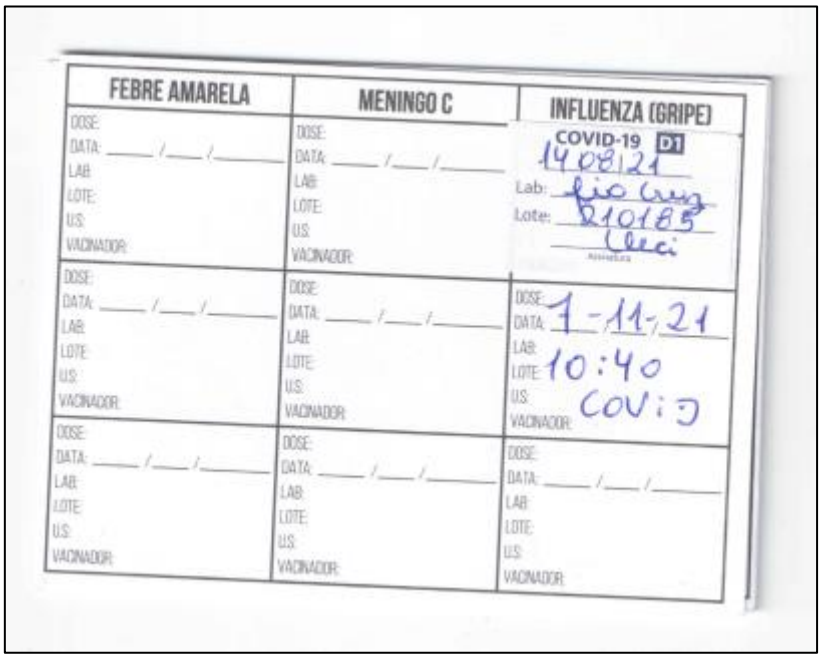

FEBRE AMARELA	MENINGO C	INFLUENZA (GRIPE)
DOSE: DATA: ___/___/___ LAB: LOTE: U.S: VACINADOR:	DOSE: DATA: ___/___/___ LAB: LOTE: U.S: VACINADOR:	COVID-19 D1 14.08.21 Lab: fio cruz Lote: 210185 Leci
DOSE: DATA: ___/___/___ LAB: LOTE: U.S: VACINADOR:	DOSE: DATA: ___/___/___ LAB: LOTE: U.S: VACINADOR:	DOSE: DATA: 1-11-21 LAB: LOTE: 10:40 U.S: COVID VACINADOR:
DOSE: DATA: ___/___/___ LAB: LOTE: U.S: VACINADOR:	DOSE: DATA: ___/___/___ LAB: LOTE: U.S: VACINADOR:	DOSE: DATA: ___/___/___ LAB: LOTE: U.S: VACINADOR:

Maria Emilia Gadelha Serra
Médica
CREMESP 63451
emilia.gadelha1@gmail.com

ANEXO 2

Resultado do Exame Laboratorial

Anticorpo anti-Heparina PF4

Laboratório Santa Catarina | Eduardo José Cury Schmid Guilherme Reverey do Prado | PNCQ | LEMC Controle de Qualidade

Sr. Bruno Oscar Graf — Idade: 28 Anos — CPF: 084.605.959-27 — RG: 55535364
Dr(a) .: Ana Caroline Benin — Data Presc: 24/08/2021
Local Coleta: CTI Adulto — Local Entrega: CTI Adulto
Convênio: Unimed — Sequência: 9203275 — Presc: 24/08/2021 21:38
Atendimento: 6708451 — Prontuário: 456730 — Imp. 09/09/2021 10:34

Anti Heparina PF4, Anticorpo (Enzimaimunoensaio)
Método..: Enzimaimunoensaio
Material: Plasma com Citrato

Resultado.....: **Positivo**

Valores de referência:
Negativo: D.O. Inferior ou igual a 0,4
Positivo: D.O. Superior a 0,4

Exame realizado em: Laboratório Diagnósticos do Brasil

Maria Emilia Gadelha Serra
Médica
CREMESP 63451
emilia.gadelha1@gmail.com

ANEXO 2 (Cont.)

Laboratório Santa Catarina

Clinilab Análises Clínicas S/C Ltda
Rua Amazonas, 301 - Blumenau - SC - CEP 89020001 - Fone: 47 3326-9830
CRF-RS 5-11649 CNPJ: 83097063000135 INSCRI. MUN.: 6602

Sr. Bruno Oscar Graf
Dra.: Ana Caroline Benin
Local Coleta: CTI Adulto
Convênio: Unimed
Atendimento: 6708451

Idade: 28 Anos CPF: 08460595927
Data: 24/08/2021
Local Entrega: CTI Adulto
Sequência: 9203275 Col. 25/08/2021 22:17
Prontuário: 456730 Imp. 22/09/2021 09:47

Anti Heparina PF4, Anticorpo (Enzimaimunoensaio)

Método..: Enzimaimunoensaio
Material: Plasma com Citrato

Resultado.....: Positivo

Valores de referência:
Negativo: D.O. Inferior ou igual a 0,4
Positivo: D.O. Superior a 0,4

Exame realizado em: Laboratório Diagnósticos do Brasil

INTERPRETAÇÃO
Com o surgimento da COVID-19, causada pelo coronavírus tipo 2 (SARS-CoV-2), iniciou-se o desenvolvimento de vacinas. No entanto, estudos recentes de sociedades internacionais apontam reação adversa também conhecida como VITT (Trombocitopenia Trombótica Induzida pela Vacina), que traz características similares à HIT (Trombocitopenia Induzida pela Heparina). Porém, na VITT os anticorpos reacionais atuam diretamente contra o complexo formado pelo PF4 e heparina. Portanto, para avaliar a VITT o exame mais indicado é VARPF4 - ANTICORPOS ANTI HEPARINA - PF4, realizado por método ELISA. É importante ressaltar que outros testes de anticorpos HIT, como por exemplo o ensaio imunoturbidimétrico de látex (LIA) e o imunoensaio quimioluminescente (CLIA) não são sensíveis para VITT, podendo apresentar resultados falsos negativos.
Fonte: Laboratório Diagnósticos do Brasil - Guia de Exames (21/09/2021)

Eduardo José Cury Schmid
CRF 2898

Documento assinado digitalmente por Eduardo José Cury Schmid

Maria Emilia Gadelha Serra
Médica
CREMESP 63451
emilia.gadelha1@gmail.com

ANEXO 2 (Cont.)

Clinilab Análises Clínicas S/C Ltda
Rua Amazonas, 301 - Blumenau - SC - CEP 89020001 - Fone: 47 3326-9830
CRF-RS 5-11649 CNPJ: 83097063000135 INSCRI. MUN.: 6602

Sr. Bruno Oscar Graf	Idade:	28 Anos	CPF: 08460595927
Dra.: Ana Caroline Benin	Data:	24/08/2021	
Local Coleta: CTI Adulto	Local Entrega:	CTI Adulto	
Convênio: Unimed	Sequência:	9203275	Col. 25/08/2021 22:17
Atendimento: 6708451	Prontuário:	456730	Imp. 22/09/2021 09:47

Anti Heparina PF4, Anticorpo (Enzimaimunoensaio)

Método..: Enzimaimunoensaio
Material: Plasma com Citrato

Resultado.....: **Positivo**

Valores de referência:
Negativo: D.O. Inferior ou igual a 0,4
Positivo: D.O. Superior a 0,4

Exame realizado em: Laboratório Diagnósticos do Brasil

INTERPRETAÇÃO
Com o surgimento da COVID-19, causada pelo coronavírus tipo 2 (SARS-CoV-2), iniciou-se o desenvolvimento de vacinas. No entanto, estudos recentes de sociedades internacionais apontam reação adversa também conhecida como VITT (Trombocitopenia Trombótica Induzida pela Vacina), que traz características similares à HIT (Trombocitopenia Induzida pela Heparina). Porém, na VITT os anticorpos reacionais atuam diretamente contra o complexo formado pelo PF4 e heparina. Portanto, para avaliar a VITT o exame mais indicado é VAHPF4 - ANTICORPOS ANTI HEPARINA - PF4, realizado por método ELISA. É importante ressaltar que outros testes de anticorpos HIT, como por exemplo o ensaio imunoturbidimétrico de látex (LIA) e o imunoensaio quimioluminescente (CLIA) não são sensíveis para VITT, podendo apresentar resultados falsos negativos.
Fonte: Laboratório Diagnósticos do Brasil - **Guia de Exames (21/09/2021)**

ALPHA GROUP
MEDICINA INTEGRATIVA

Maria Emilia Gadelha Serra
Médica
CREMESP 63451
emilia.gadelha1@gmail.com

ANEXO 3

Certidão de Óbito de Bruno Oscar Graf

REGISTRO CIVIL - SÔNIA BRAGA VARELA - BLUMENAU - SC

REPÚBLICA FEDERATIVA DO BRASIL
REGISTRO CIVIL DAS PESSOAS NATURAIS

CERTIDÃO DE ÓBITO

NOME:
BRUNO OSCAR GRAF

CPF
084.605.959-27

MATRÍCULA:
104810 01 55 2021 4 00191 062 0068151 21

SEXO: Masculino | COR: branca | ESTADO CIVIL E IDADE: solteiro - 28 anos

NATURALIDADE: Blumenau - SC | DOCUMENTO DE IDENTIFICAÇÃO: 5553536 - SSP/SC | ELEITOR: SIM

FILIAÇÃO E RESIDÊNCIA: OSCAR JOSÉ GRAF e ARLENE TERESINHA FERRARI GRAF - rua Lydia Zwicker, 761, Garcia, Blumenau - SC

DATA E HORA DE FALECIMENTO: Vinte e seis de agosto de dois mil e vinte e um - 06:22 | DIA: 26 | MÊS: 08 | ANO: 2021

LOCAL DE FALECIMENTO: Hospital Santa Catarina, à(em) rua Amazonas, 301, bairro Ribeirão Fresco, Blumenau-SC

CAUSA DA MORTE: AVC hemorrágico. Trombocitopenia trombótica imune

SEPULTAMENTO/CREMAÇÃO (município e cemitério, se conhecido): cemitério da rua São José, à(em) rua São José, 419, bairro Centro, Blumenau-SC | DECLARANTE: OSCAR JOSÉ GRAF

NOME E NÚMERO DO DOCUMENTO DO MÉDICO QUE ATESTOU O ÓBITO: Doutora Georgeane Floriani de CRM nº12317 e Doutor Tiago A B Padilha de CRM nº8406

AVERBAÇÕES/ANOTAÇÕES A ACRESCER: Nascido em 28/10/1992, advogado. Não deixou filhos. Não deixou bens a inventariar, era eleitor e não deixou testamento.

Poder Judiciário
Estado de Santa Catarina
Selo Digital de Fiscalização
Isento
GEY01672-R8UQ
Confira os dados do ato em:
http://selo.tjsc.jus.br/

NOME DO OFÍCIO:
Cartorio Braga Varela
OFICIAL REGISTRADOR:
Sônia Mary Braga Varela
MUNICÍPIO/COMARCA/UF: Blumenau - SC
ENDEREÇO:
Rua XV de Novembro, 759, 2º piso, salas 40/46, Centro - CEP: 89010-902 - www.registrocivilblumenau.com.br

O conteúdo da certidão é verdadeiro. Dou fé.

Blumenau - SC, 30 de agosto de 2021

DAIANI LUCIA AMORIM
Escrevente Substituta

ARPENBRASIL BA 012502530 BRP

Maria Emilia Gadelha Serra
Médica
CREMESP 63451
emilia.gadelha1@gmail.com

ANEXO 3 (Cont.)

REGISTRO CIVIL - SONIA BRAGA VARELA - BLUMENAU - SC

REPÚBLICA FEDERATIVA DO BRASIL
REGISTRO CIVIL DAS PESSOAS NATURAIS

CERTIDÃO DE ÓBITO

NOME:
BRUNO OSCAR GRAF

CPF: 084.605.959-27

MATRÍCULA:
104810 01 55 2021 4 00191 062 0068151 21

SEXO: Masculino | COR: branca | ESTADO CIVIL E IDADE: solteiro - 28 anos

NATURALIDADE: Blumenau - SC | DOCUMENTO DE IDENTIFICAÇÃO: 5553536 - SSP/SC | ELEITOR: SIM

FILIAÇÃO E RESIDÊNCIA: OSCAR JOSÉ GRAF e ARLENE TERESINHA FERRARI GRAF - rua Lydia Zwicker, 761, Garcia, Blumenau - SC

DATA E HORA DE FALECIMENTO: Vinte e seis de agosto de dois mil e vinte e um - 06:22 | DIA: 26 | MÊS: 08 | ANO: 2021

LOCAL DE FALECIMENTO: Hospital Santa Catarina, à(em) rua Amazonas, 301, bairro Ribeirão Fresco, Blumenau-SC

CAUSA DA MORTE: AVC hemorrágico. Trombocitopenia trombótica imune

SEPULTAMENTO/CREMAÇÃO (município e cemitério, se conhecido): cemitério da rua São José, à(em) rua São José, 419, bairro Centro, Blumenau-SC | DECLARANTE: OSCAR JOSÉ GRAF

NOME E NÚMERO DO DOCUMENTO DO MÉDICO QUE ATESTOU O ÓBITO: Doutora Georgeane Floriani de CRM nº12317 e Doutor Tiago A B Padilha de CRM nº8406

AVERBAÇÕES/ANOTAÇÕES A ACRESCER: Nascido em 28/10/1992, advogado. Não deixou filhos. Não deixou bens a inventariar, era eleitor e não deixou testamento.

Maria Emilia Gadelha Serra
Médica
CREMESP 63451
emilia.gadelha1@gmail.com

ANEXO 4

Referências Bibliográficas

1. https://pubmed.ncbi.nlm.nih.gov/34033367/

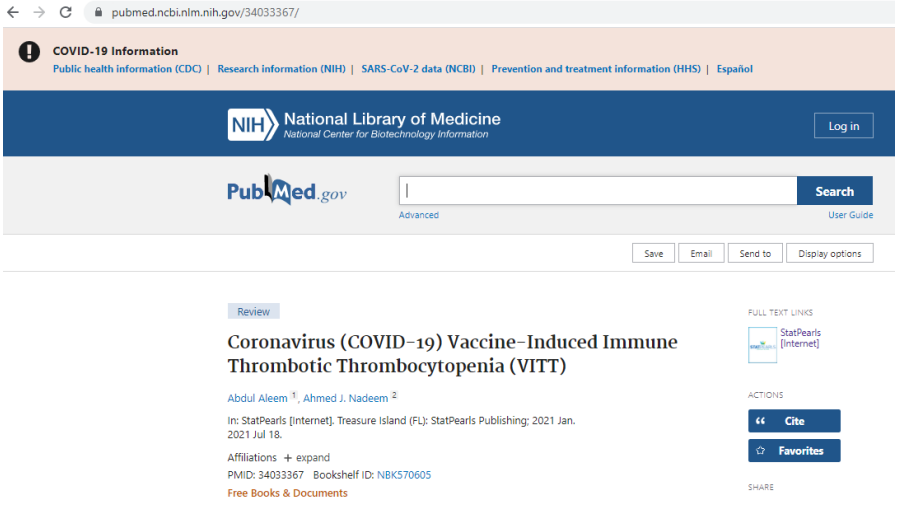

In late February 2021, a new clinical syndrome characterized by thrombosis at atypical sites combined with thrombocytopenia was observed in multiple patients' days after vaccination with the ChAdOx1 nCoV-19 vaccine. In April 2021, similar clinical sequelae were reported in patients after vaccination with the Ad26.COV2. S vaccine. Preceding the approval of these vaccines, the clinical constellation of this new syndrome was not observed in clinical trials of the ChAdOx1 nCoV-19 vaccine, and a single case was observed in the Ad26.COV2. S vaccine trial recipient. Furthermore, the incidence of major adverse effects has remained exceptionally low following the vaccination of more than 400 million people worldwide. This novel clinical syndrome demonstrated striking similarities to heparin-induced thrombocytopenia; however, in the absence of prior heparin exposure was named vaccine-induced immune thrombotic thrombocytopenia (VITT). It is also known as vaccine-induced prothrombotic immune thrombocytopenia (VIPIT) in some European nations and Canada. Conversely, of more than 180 million doses of BNT162b2 or mRNA-1273 vaccines administered so far, this clinical syndrome has not been reported.

Per the American Society of Hematology, vaccine-induced immune thrombotic thrombocytopenia (VITT) is defined as a clinical syndrome characterized by all of the below described abnormal laboratory and radiologic abnormalities occurring in individuals 4 to 30 days after vaccination with Ad26.COV2. S or ChAdOx1 nCoV-19 vaccines.

- Development of thrombosis at uncommon sites includes cerebral venous sinus thrombosis (CSVT)/splanchnic venous thrombosis.
- Mild to severe thrombocytopenia. However, a normal platelet count does not exclude the possibility of this syndrome in its early stages.
- Positive antibodies against platelet factor 4(PF4) identified by enzyme-linked immunosorbent assay (ELISA) assay.

Maria Emilia Gadelha Serra
Médica
CREMESP 63451
emilia.gadelha1@gmail.com

ANEXO 4 (Cont.)

2. https://onlinelibrary.wiley.com/doi/10.1111/jth.15341

pubmed.ncbi.nlm.nih.gov/34018298/

COVID-19 Information
Public health information (CDC) | Research information (NIH) | SARS-CoV-2 data (NCBI) | Prevention and treatment information (HHS) | Español

NIH National Library of Medicine
National Center for Biotechnology Information
Log in

PubMed.gov
Search
Advanced
User Guide

Save | Email | Send to | Display options

J Thromb Haemost. 2021 Jun;19(6):1585-1588. doi: 10.1111/jth.15341. Epub 2021 May 20.

Recommendations for the clinical and laboratory diagnosis of VITT against COVID-19: Communication from the ISTH SSC Subcommittee on Platelet Immunology

Ishac Nazy [1,2], Ulrich J Sachs [3], Donald M Arnold [1,2], Steven E McKenzie [4], Phil Choi [5,6], Karina Althaus [7,8], Maria Therese Ahlen [9], Ruchika Sharma [10], Rachael F Grace [11], Tamam Bakchoul [12]

Affiliations + expand

PMID: 34018298 PMCID: PMC8250233 DOI: 10.1111/jth.15341
Free PMC article

FULL TEXT LINKS
WILEY Full Text Article
PMC FREE Full text

ACTIONS
Cite
Favorites

SHARE

Abstract

Vaccine administration is under way worldwide to combat the current COVID-19 pandemic. The newly developed vaccines are highly effective with minimal adverse effects. Recently, the AstraZeneca ChadOx1 nCov-19 vaccine has raised public alarm with concerns regarding the rare, but serious, development of thrombotic events, now known as vaccine-induced immune thrombotic thrombocytopenia (VITT). These thrombotic events appear similar to heparin-induced thrombocytopenia, both clinically and pathologically. In this manuscript, the ISTH SSC Subcommittee on Platelet Immunology outlines guidelines on how to recognize, diagnose and manage patients with VITT.

Keywords: AstraZeneca ChadOx1 nCov-19 vaccine; COVID-19; platelet activation; thrombocytopenia; thrombosis.

© 2021 International Society on Thrombosis and Haemostasis.

Conflict of interest statement

The authors declare no competing financial interests.

Maria Emilia Gadelha Serra
Médica
CREMESP 63451
emilia.gadelha1@gmail.com

ANEXO 4 (Cont.)

3. https://www.nejm.org/doi/full/10.1056/NEJMoa2104882

Abstract

Background: Several cases of unusual thrombotic events and thrombocytopenia have developed after vaccination with the recombinant adenoviral vector encoding the spike protein antigen of severe acute respiratory syndrome coronavirus 2 (SARS-CoV-2) (ChAdOx1 nCov-19, AstraZeneca). More data were needed on the pathogenesis of this unusual clotting disorder.

Methods: We assessed the clinical and laboratory features of 11 patients in Germany and Austria in whom thrombosis or thrombocytopenia had developed after vaccination with ChAdOx1 nCov-19. We used a standard enzyme-linked immunosorbent assay to detect platelet factor 4 (PF4)-heparin antibodies and a modified (PF4-enhanced) platelet-activation test to detect platelet-activating antibodies under various reaction conditions. Included in this testing were samples from patients who had blood samples referred for investigation of vaccine-associated thrombotic events, with 28 testing positive on a screening PF4-heparin immunoassay.

Results: Of the 11 original patients, 9 were women, with a median age of 36 years (range, 22 to 49). Beginning 5 to 16 days after vaccination, the patients presented with one or more thrombotic events, with the exception of 1 patient, who presented with fatal intracranial hemorrhage. Of the patients with one or more thrombotic events, 9 had cerebral venous thrombosis, 3 had splanchnic-vein thrombosis, 3 had pulmonary embolism, and 4 had other thromboses; of these patients, 6 died. Five patients had disseminated intravascular coagulation. None of the patients had received heparin before symptom onset. All 28 patients who tested positive for antibodies against PF4-heparin tested positive on the platelet-activation assay in the presence of PF4 independent of heparin. Platelet activation was inhibited by high levels of heparin, Fc receptor-blocking monoclonal antibody, and immune globulin (10 mg per milliliter). Additional studies with PF4 or PF4-heparin affinity purified antibodies in 2 patients confirmed PF4-dependent platelet activation.

Conclusions: Vaccination with ChAdOx1 nCov-19 can result in the rare development of immune thrombotic thrombocytopenia mediated by platelet-activating antibodies against PF4, which clinically mimics autoimmune heparin-induced thrombocytopenia. (Funded by the German Research Foundation.).

Copyright © 2021 Massachusetts Medical Society.

Maria Emilia Gadelha Serra
Médica
CREMESP 63451
emilia.gadelha1@gmail.com

ANEXO 4 (Cont.)

4. https://pubmed.ncbi.nlm.nih.gov/34136745/

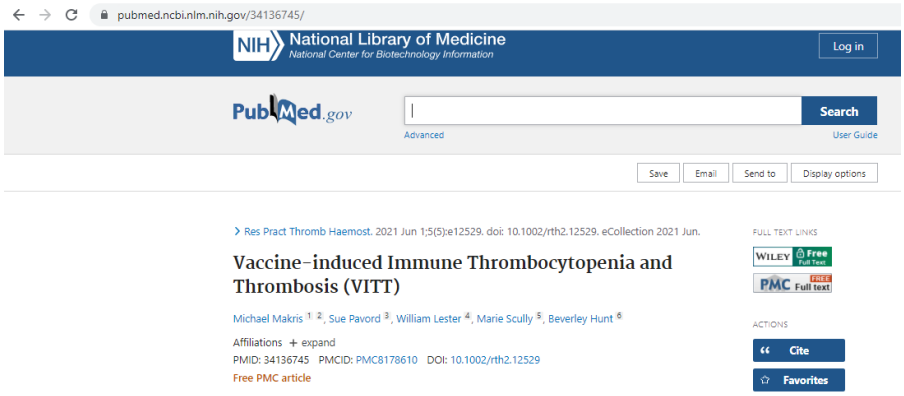

TABLE 1

Summary of the reported cases of vaccine-induced immune thrombocytopenia and thrombosis

Reference	Vaccine	Country/Area	Number	Age, y, mean (range)	Sex	Primary thrombosis type	Platelet count, $\times 10^9$/L, mean (range)	Outcome
Schultz et al[3]	AZ	Norway	5	40.8 (32–54)	4 F, 1 M	4 CVST 1 portal vein	27 (10-70)	Fatal 60%
Greinacher et al[4]	AZ	Germany and Austria	11	36 (22-49)	9 F, 2 M	9 CVST 1 PE	35 (8–107)	Fatal 55%
Scully et al[5]	AZ	United Kingdom	23	46 (21–77)	13 F, 10 M	13 CVST 4 PE 1 DVT 2 MCA strokes 2 portal vein	44 (7-113)	Fatal 30%
Muir et al[6]	J&J	United States	1	48	1 F	1 CVST	13	Critically ill at reporting

Abbreviations: AZ, AstraZeneca; CVST, cerebral venous sinus thrombosis; DVT, deep vein thrombosis; F, female; J&J, Johnson & Johnson; M, male; MCA, middle cerebral artery territory; PE, pulmonary embolism.

Maria Emilia Gadelha Serra
Médica
CREMESP 63451
emilia.gadelha1@gmail.com

ANEXO 4 (Cont.)

5. https://pubmed.ncbi.nlm.nih.gov/33835768/

pubmed.ncbi.nlm.nih.gov/33835768/

NIH National Library of Medicine
National Center for Biotechnology Information
Log in

PubMed.gov
Search
Advanced
User Guide

Save | Email | Send to | Display options

Case Reports > N Engl J Med. 2021 Jun 3;384(22):2124-2130. doi: 10.1056/NEJMoa2104882. Epub 2021 Apr 9.

Thrombosis and Thrombocytopenia after ChAdOx1 nCoV-19 Vaccination

Nina H Schultz [1], Ingvild H Sørvoll [1], Annika E Michelsen [1], Ludvig A Munthe [1], Fridtjof Lund-Johansen [1], Maria T Ahlen [1], Markus Wiedmann [1], Anne-Hege Aamodt [1], Thor H Skattør [1], Geir E Tjønnfjord [1], Pål A Holme [1]

Affiliations + expand

PMID: 33835768 PMCID: PMC8112568 DOI: 10.1056/NEJMoa2104882

Free PMC article

FULL TEXT LINKS
NEJM FULL TEXT
PMC FREE Full text

ACTIONS
Cite
Favorites

SHARE

Abstract

We report findings in five patients who presented with venous thrombosis and thrombocytopenia 7 to 10 days after receiving the first dose of the ChAdOx1 nCoV-19 adenoviral vector vaccine against coronavirus disease 2019 (Covid-19). The patients were health care workers who were 32 to 54 years of age. All the patients had high levels of antibodies to platelet factor 4-polyanion complexes; however, they had had no previous exposure to heparin. Because the five cases occurred in a population of more than 130,000 vaccinated persons, we propose that they represent a rare vaccine-related variant of spontaneous heparin-induced thrombocytopenia that we refer to as vaccine-induced immune thrombotic thrombocytopenia.

Copyright © 2021 Massachusetts Medical Society.

Maria Emilia Gadelha Serra
Médica
CREMESP 63451
emilia.gadelha1@gmail.com

ANEXO 4 (Cont.)

6. https://www.nejm.org/doi/pdf/10.1056/NEJMoa2109908?listPDF=true

pubmed.ncbi.nlm.nih.gov/34379914/

COVID-19 Information
Public health information (CDC) | Research information (NIH) | SARS-CoV-2 data (NCBI) | Prevention and treatment information (HHS) | Español

NIH National Library of Medicine
National Center for Biotechnology Information
Log in

PubMed.gov
Search
Advanced User Guide

Save Email Send to Display options

N Engl J Med. 2021 Aug 11. doi: 10.1056/NEJMoa2109908. Online ahead of print.

Clinical Features of Vaccine-Induced Immune Thrombocytopenia and Thrombosis

Sue Pavord [1], Marie Scully [1], Beverley J Hunt [1], William Lester [1], Catherine Bagot [1], Brian Craven [1], Alex Rampotas [1], Gareth Ambler [1], Mike Makris [1]
Affiliations + expand
PMID: 34379914 DOI: 10.1056/NEJMoa2109908

FULL TEXT LINKS
NEJM FULL TEXT
ACTIONS
Cite
Favorites
SHARE

Abstract

Background: Vaccine-induced immune thrombocytopenia and thrombosis (VITT) is a new syndrome associated with the ChAdOx1 nCoV-19 adenoviral vector vaccine against severe acute respiratory syndrome coronavirus 2. Data are lacking on the clinical features of and the prognostic criteria for this disorder.

Methods: We conducted a prospective cohort study involving patients with suspected VITT who presented to hospitals in the United Kingdom between March 22 and June 6, 2021. Data were collected with the use of an anonymized electronic form, and cases were identified as definite or probable VITT according to prespecified criteria. Baseline characteristics and clinicopathological features of the patients, risk factors, treatment, and markers of poor prognosis were determined.

Results: Among 294 patients who were evaluated, we identified 170 definite and 50 probable cases of VITT. All the patients had received the first dose of ChAdOx1 nCoV-19 vaccine and presented 5 to 48 days (median, 14) after vaccination. The age range was 18 to 79 years (median, 48), with no sex preponderance and no identifiable medical risk factors. Overall mortality was 22%. The odds of death increased by a factor of 2.7 (95% confidence interval [CI], 1.4 to 5.2) among patients with cerebral venous sinus thrombosis, by a factor of 1.7 (95% CI, 1.3 to 2.3) for every 50% decrease in the baseline platelet count, by a factor of 1.2 (95% CI, 1.0 to 1.3) for every increase of 10,000 fibrinogen-equivalent units in the baseline d-dimer level, and by a factor of 1.7 (95% CI, 1.1 to 2.5) for every 50% decrease in the baseline fibrinogen level. Multivariate analysis identified the baseline platelet count and the presence of intracranial hemorrhage as being independently associated with death; the observed mortality was 73% among patients with platelet counts below 30,000 per cubic millimeter and intracranial hemorrhage.

Conclusions: The high mortality associated with VITT was highest among patients with a low platelet count and intracranial hemorrhage. Treatment remains uncertain, but identification of prognostic markers may help guide effective management. (Funded by the Oxford University Hospitals NHS Foundation Trust.).

Copyright © 2021 Massachusetts Medical Society.

Maria Emilia Gadelha Serra
Médica
CREMESP 63451
emilia.gadelha1@gmail.com

ANEXO 4 (Cont.)

7. https://www.nejm.org/doi/full/10.1056/NEJMoa2105385

pubmed.ncbi.nlm.nih.gov/33861525/

COVID-19 Information
Public health information (CDC) | Research information (NIH) | SARS-CoV-2 data (NCBI) | Prevention and treatment information (HHS) | Español

NIH National Library of Medicine
National Center for Biotechnology Information
Log in

PubMed.gov
Search
Advanced User Guide

Save Email Send to Display options

N Engl J Med. 2021 Jun 10;384(23):2202-2211. doi: 10.1056/NEJMoa2105385. Epub 2021 Apr 16.

Pathologic Antibodies to Platelet Factor 4 after ChAdOx1 nCoV-19 Vaccination

Marie Scully [1], Deepak Singh [1], Robert Lown [1], Anthony Poles [1], Tom Solomon [1], Marcel Levi [1], David Goldblatt [1], Pavel Kotoucek [1], William Thomas [1], William Lester [1]
Affiliations + expand
PMID: 33861525 PMCID: PMC8112532 DOI: 10.1056/NEJMoa2105385
Free PMC article

FULL TEXT LINKS
NEJM FULL TEXT
PMC FREE Full text

ACTIONS
Cite
Favorites

Abstract

Background: The mainstay of control of the coronavirus disease 2019 (Covid-19) pandemic is vaccination against severe acute respiratory syndrome coronavirus 2 (SARS-CoV-2). Within a year, several vaccines have been developed and millions of doses delivered. Reporting of adverse events is a critical postmarketing activity.

Methods: We report findings in 23 patients who presented with thrombosis and thrombocytopenia 6 to 24 days after receiving the first dose of the ChAdOx1 nCoV-19 vaccine (AstraZeneca). On the basis of their clinical and laboratory features, we identify a novel underlying mechanism and address the therapeutic implications.

Results: In the absence of previous prothrombotic medical conditions, 22 patients presented with acute thrombocytopenia and thrombosis, primarily cerebral venous thrombosis, and 1 patient presented with isolated thrombocytopenia and a hemorrhagic phenotype. All the patients had low or normal fibrinogen levels and elevated d-dimer levels at presentation. No evidence of thrombophilia or causative precipitants was identified. Testing for antibodies to platelet factor 4 (PF4) was positive in 22 patients (with 1 equivocal result) and negative in 1 patient. On the basis of the pathophysiological features observed in these patients, we recommend that treatment with platelet transfusions be avoided because of the risk of progression in thrombotic symptoms and that the administration of a nonheparin anticoagulant agent and intravenous immune globulin be considered for the first occurrence of these symptoms.

Conclusions: Vaccination against SARS-CoV-2 remains critical for control of the Covid-19 pandemic. A pathogenic PF4-dependent syndrome, unrelated to the use of heparin therapy, can occur after the administration of the ChAdOx1 nCoV-19 vaccine. Rapid identification of this rare syndrome is important because of the therapeutic implications.

Copyright © 2021 Massachusetts Medical Society.

Maria Emilia Gadelha Serra
Médica
CREMESP 63451
emilia.gadelha1@gmail.com

ANEXO 4 (Cont.)

8. https://www.ncbi.nlm.nih.gov/pmc/articles/PMC8129797/

https://www.ncbi.nlm.nih.gov/pmc/articles/PMC8129797/

NCBI Resources How To

PMC US National Library of Medicine National Institutes of Health

PMC Advanced Journal list

COVID-19 Information

Public health information (CDC) | Research information (NIH) | SARS-CoV-2 data (NCBI) | Prevention and treatment

Try out PMC Labs and tell us what you think. Learn More.

Journal List › Blood › PMC8129797

blood

Blood. 2021 Jul 29; 138(4): 299–303.
Prepublished online 2021 May 14. doi: 10.1182/blood.2021012217

PMCID: PMC8129797
PMID: 33988688

Frequency of positive anti-PF4/polyanion antibody tests after COVID-19 vaccination with ChAdOx1 nCoV-19 and BNT162b2

Thomas Thiele,[1,*] Lena Ulm,[2,*] Silva Holtfreter,[3,*] Linda Schönborn,[1] Sven Olaf Kuhn,[4] Christian Scheer,[4] Theodore E. Warkentin,[5,6] Barbara M. Bröker,[3] Karsten Becker,[2] Konstanze Aurich,[1] Kathleen Selleng,[1] Nils-Olaf Hübner,[7] and Andreas Greinacher[1]

Abstract

Go to:

Vaccination using the adenoviral vector COVID-19 vaccine ChAdOx1 nCoV-19 (AstraZeneca) has been associated with rare vaccine-induced immune thrombotic thrombocytopenia (VITT). Affected patients test strongly positive in platelet factor 4 (PF4)/polyanion enzyme immunoassays (EIAs), and serum-induced platelet activation is maximal in the presence of PF4. We determined the frequency of anti-PF4/polyanion antibodies in healthy vaccinees and assessed whether PF4/polyanion EIA$^+$ sera exhibit platelet-activating properties after vaccination with ChAdOx1 nCoV-19 (n = 138) or BNT162b2 (BioNTech/Pfizer; n = 143). In total, 19 of 281 participants tested positive for anti-PF4/polyanion antibodies postvaccination (All: 6.8% [95% confidence interval (CI), 4.4-10.3]; BNT162b2: 5.6% [95% CI, 2.9-10.7]; ChAdOx1 nCoV-19: 8.0% [95% CI, 4.5% to 13.7%]). Optical densities were mostly low (between 0.5 and 1.0 units; reference range, <0.50), and none of the PF4/polyanion EIA$^+$ samples induced platelet activation in the presence of PF4. We conclude that positive PF4/polyanion EIAs can occur after severe acute respiratory syndrome coronavirus 2 vaccination with both messenger RNA- and adenoviral vector-based vaccines, but many of these antibodies likely have minor (if any) clinical relevance. Accordingly, low-titer positive PF4/polyanion EIA results should be interpreted with caution when screening asymptomatic individuals after vaccination against COVID-19. Pathogenic platelet-activating antibodies that cause VITT do not occur commonly following vaccination.

Maria Emilia Gadelha Serra
Médica
CREMESP 63451
emilia.gadelha1@gmail.com

ANEXO 4 (Cont.)

https://www.ncbi.nlm.nih.gov/pmc/articles/PMC8129797/

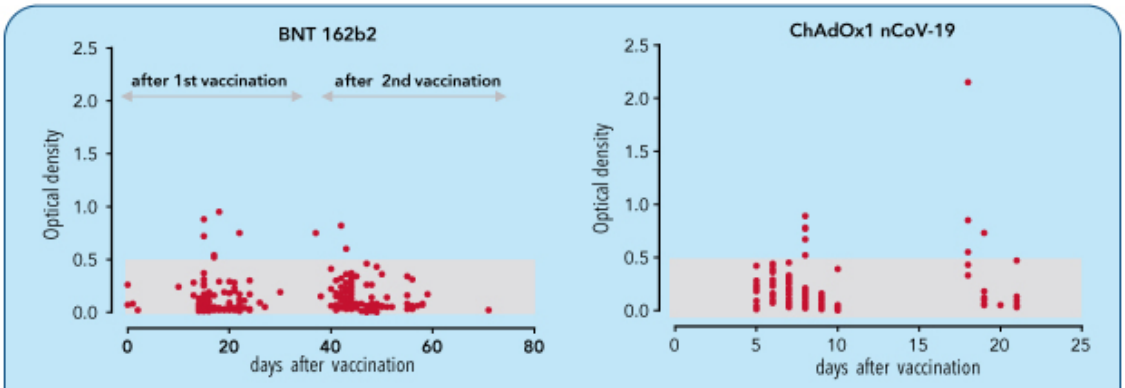

Postvaccination PF4/polyanion IgG

Vaccine	BNT162b2	ChAdOx1 nCoV-19	Total
Total (n)	143	138	281
PF4/polyanion EIA positive, n (%)	8 (5.5)	11 (8.0)	19 (6.8)
PF4 platelet activation assay	0	0	0

Pathogenic platelet-activating antibodies that cause VITT do not occur commonly following vaccination. Therefore, postive PF4/polyanion EIA results should be interpreted with caution when screening asymptomatic individuals after vaccination against Covid-19.

Maria Emilia Gadelha Serra
Médica
CREMESP 63451
emilia.gadelha1@gmail.com

ANEXO 4 (Cont.)

9. https://www.ncbi.nlm.nih.gov/pmc/articles/PMC8220408/

https://www.ncbi.nlm.nih.gov/pmc/articles/PMC8220408/

NCBI Resources How To

PMC US National Library of Medicine National Institutes of Health

PMC Advanced Journal list

COVID-19 Information

Public health information (CDC) | Research information (NIH) | SARS-CoV-2 data (NCBI) | Prevention and treatmen

Try out PMC Labs and tell us what you think. Learn More.

Journal List › Elsevier Public Health Emergency Collection › PMC8220408

Elsevier Public Health Emergency Collection

Public Health Emergency COVID-19 Initiative

J Autoimmun. 2021 Aug; 122: 102685.
Published online 2021 Jun 23. doi: 10.1016/j.jaut.2021.102685

PMCID: PMC8220408
PMID: 34174723

Blood clots and bleeding events following BNT162b2 and ChAdOx1 nCoV-19 vaccine: An analysis of European data

Luigi Cari,[a] Paolo Fiore,[a] Mahdieh Naghavi Alhosseini,[a] Gianni Sava,[b] and Giuseppe Nocentini[a,*]

Abstract

Go to:

The involvement of viruses and SARS-CoV-2 in autoimmune diseases is well known. The recent demonstration that ChAdOx1 nCoV-19 Covid-19 (AstraZeneca) vaccine (ChA) favors the production of anti-platelet factor 4 (anti-PF4) antibodies, blood clots, and thrombocytopenia raises the question of whether other anti-CoViD-19 vaccines favor the same patterns of events.

We assessed the frequency of severe adverse events (SAEs) documented in the EudraVigilance European database up to April 16, 2021 related to thrombocytopenia, bleeding, and blood clots in recipients of ChA compared to that of recipients of the BNT162b2 Covid-19 (Pfizer/BioNTech) vaccine (BNT).

ChA administration was associated with a much higher frequency of SAEs in each AE Reaction Group as compared with that elicited by BNT. When considering AEs caused by thrombocytopenia, bleeding and blood clots, we observed 33 and 151 SAEs/1 million doses in BNT and ChA recipients, respectively. When considering patients with AEs related to cerebral/splanchnic venous thrombosis, and/or thrombocytopenia, we documented 4 and 30 SAEs and 0.4 and 4.8 deaths/1 million doses for BNT and ChA recipients, respectively. The highest risk following ChA vaccination is in young people and, likely, women of reproductive age, as suggested by hypothesized scenarios.

In conclusion, the immune reaction promoted by ChA vaccine may lead to not only thrombocytopenia and cerebral/splanchnic venous thrombosis but also other thrombotic and thromboembolic SAEs. These events are not favored by BNT vaccine. Our study may help in the evaluation of the benefit/risk profile of the ChA vaccine considering the epidemic curve present in a country.

Keywords: Anti-CoViD-19 vaccines, Severe adverse events, Venous thrombosis, Thrombocytopenia, Risk factors

Maria Emilia Gadelha Serra
Médica
CREMESP 63451
emilia.gadelha1@gmail.com

ANEXO 4 (Cont.)

10. https://pubmed.ncbi.nlm.nih.gov/34365148/

pubmed.ncbi.nlm.nih.gov/34365148/

National Library of Medicine
National Center for Biotechnology Information

Log in

PubMed.gov

Search

Advanced User Guide

Save Email Send to Display options

Review J Neurol Sci. 2021 Sep 15;428:117607. doi: 10.1016/j.jns.2021.117607. Epub 2021 Aug 3.

Vaccine-induced immune thrombotic thrombocytopenia and cerebral venous sinus thrombosis post COVID-19 vaccination; a systematic review

Maryam Sharifian-Dorche [1], Mohammad Bahmanyar [2], Amirhossein Sharifian-Dorche [3], Pegah Mohammadi [4], Masood Nomovi [5], Ashkan Mowla [6]

Affiliations + expand

PMID: 34365148 PMCID: PMC8330139 DOI: 10.1016/j.jns.2021.117607
Free PMC article

FULL TEXT LINKS
ELSEVIER FULL-TEXT ARTICLE
PMC FREE Full text

ACTIONS
Cite
Favorites

SHARE

Abstract

Introduction: The common reported adverse effects of COVID-19 vaccination consist of the injection site's local reaction followed by several non-specific flu-like symptoms. However, rare cases of vaccine-induced immune thrombotic thrombocytopenia (VITT) and cerebral venous sinus thrombosis (CVST) after viral vector vaccines (ChAdOx1 nCoV-19 vaccine, Ad26.COV2 vaccine) have been reported. Herein we systemically reviewed the reported cases of CVST and VITT following the COVID-19 vaccination.

Methods: This systematic review was performed according to the Preferred Reporting Items for Systematic Reviews and Meta-Analyses (PRISMA) statement. We searched PubMed until May 19, 2021, and the following Keywords were used: COVID Vaccine & Neurology, AstraZeneca COVID vaccine, ChAdOx1 nCoV-19 COVID vaccine, AZD1222 COVID vaccine, Janssen COVID vaccine, Johnson & Johnson COVID vaccine, Ad26.COV2 COVID vaccine. The authors evaluated the abstracts and titles of each article for screening and inclusion. English reports about post-vaccine CVST and VITT in humans were collected.

Results: Until May 19, we found 877 articles with the searched terms. We found 12 articles, which overall present clinical features of 36 patients with CVST and VITT after the ChAdOx1 nCoV-19 vaccine. Moreover, two articles were noted, which present 13 patients with CVST and VITT after Ad26.COV2 vaccine. The majority of the patients were females. Symptom onset occurred within one week after the first dose of vaccination (Range 4-19 days). Headache was the most common presenting symptom. Intracerebral hemorrhage (ICH) and/or Subarachnoid hemorrhage (SAH) were reported in 49% of the patients. The platelet count of the patients was between 5 and 127 cells$\times 10^9$/l, PF4 IgG Assay and d-Dimer were positive in the majority of the reported cases. Among 49 patients with CVST, at least 19 patients died (39%) due to complications of CVST and VITT.

Conclusion: Health care providers should be familiar with the clinical presentations, pathophysiology, diagnostic criteria, and management consideration of this rare but severe and potentially fatal complication of the COVID-19 vaccination. Early diagnosis and quick initiation of the treatment may help to provide patients with a more favorable neurological outcome.

Keywords: Ad26.COV2 vaccine; Cerebral venous sinus thrombosis; ChAdOx1 nCoV-19 vaccine; Vaccine-induced immune thrombotic thrombocytopenia.

Copyright © 2021 Elsevier B.V. All rights reserved.

Maria Emilia Gadelha Serra
Médica
CREMESP 63451
emilia.gadelha1@gmail.com

ANEXO 4 (Cont.)

11. https://pubmed.ncbi.nlm.nih.gov/34407607/

pubmed.ncbi.nlm.nih.gov/34407607/

NIH National Library of Medicine
National Center for Biotechnology Information

Log in

PubMed.gov

Search

Advanced User Guide

Save Email Send to Display options

Haematologica. 2021 Aug 19. doi: 10.3324/haematol.2021.279289. Online ahead of print.

Interactions of adenoviruses with platelets and coagulation and the vaccine-associated autoimmune thrombocytopenia thrombosis syndrome

Paolo Gresele [1], Stefania Momi [2], Rossella Marcucci [3], Francesco Ramundo [4], Valerio De Stefano [4], Armando Tripodi [5]

Affiliations + expand

PMID: 34407607 DOI: 10.3324/haematol.2021.279289

Free article

FULL TEXT LINKS

haematologica

ACTIONS

Cite

Favorites

SHARE

Abstract

The Covid-19 pandemic has heavily impacted global health and economy and vaccination remains the primary way of controlling the infection. During the ongoing vaccination campaign some unexpected thrombotic events have emerged in subjects who recently received the AstraZeneca Vaxzevria vaccine or the Johnson and Johnson (Janssen) vaccine, two adenovirus vector-based vaccines. Epidemiological studies confirm that the observed/expected rate of these unusual thromboses is abnormally increased, especially in women in the fertile age. The characteristics of this complication, with venous thromboses at unusual sites, most frequently cerebral vein sinus but also splanchnic, often multiple associated thromboses, thrombocytopenia, and sometimes disseminated intravascular coagulation, are unique and the time course and tumultuous evolution are suggestive of an acute immunological reaction, and indeed platelet-activating anti-PF4 antibodies have been detected in a large fraction of the affected patients. Several data suggest that adenoviruses may interact with platelets, the endothelium and the blood coagulation system. Here we review the interactions between adenoviral vectors and the haemostatic system of possible relevance for the vaccine associated thrombotic thrombocytopenia syndrome, we analyse systematically the clinical data on the reported thrombotic complications of adenovirus-based therapeutics and discuss all the current hypotheses on the mechanisms triggering this novel syndrome. Although considering current evidence the benefit of vaccination clearly outweighs the potential risks, it is of paramount importance to fully unravel the mechanisms leading to the vaccine associated thrombotic thrombocytopenia syndrome and to identify prognostic factors through further research.

Mª Emília Gadelha Serra
CRM 63451